

Arabinoxylan Rice Bran (MGN-3) Enhances the Effects of Interventional Therapies for the Treatment of Hepatocellular Carcinoma: A Three-year Randomized Clinical Trial

MAI HONG BANG¹, TRAN VAN RIEP², NGUYEN TIEN THINH¹, LE HUU SONG³,
TRINH TUAN DUNG⁴, LE VAN TRUONG⁵, LE VAN DON⁶, THAI DOAN KY¹,
DEYU PAN⁷, MAGDA SHAHEEN⁷ and MAMDOOH GHONEUM⁸

Departments of ¹Hepatogastroenterology, ²Imaging and Functional Diagnosis, ³Molecular Biology, ⁴Pathology, ⁵Cardiovascular Intervention, and ⁶Immunology, The 108 Military Central Hospital, Hanoi, Vietnam; Departments of ⁷Internal Medicine and ⁸Otolaryngology, Charles Drew University of Medicine and Science, Los Angeles, CA, U.S.A.

Abstract. *Background and Aims:* This study examined the efficacy of arabinoxylan rice bran (MGN-3) in conjunction with an interventional therapy (IT) for the treatment of hepatocellular carcinoma patients. *Patients and Methods:* A total of sixty-eight patients with hepatocellular carcinoma (stages I and II) participated in the study. Patients were randomized to receive IT (30 patients, control group) or IT+MGN-3 (38 patients), and randomly divided into two groups using a computer-generated randomization list. Patients and investigators were blinded. IT included transarterial oily chemoembolization (TOCE) or a combination of TOCE and percutaneous ethanol injection treatment (PEIT). *Results:* Patients in the IT+MGN-3 group showed: (i) lower recurrence of the disease, 31.6% (12/38), as compared to 46.7% (14/30) for the control; (ii) higher survival after the second year, 35%, as compared to 6.7% for the control; (iii) significantly lower alpha-fetoprotein level, a 38% decrease ($p=0.0001$), as compared to baseline value, while the control showed no significant change; and (iv) a significant decrease in tumor volume, in contrast to the control, which showed no significant change. When the results were analyzed according to each IT modality, MGN-3+IT sub-groups displayed a greater response to treatment, in every aspect examined, than the IT sub-groups alone. However, the patients in the MGN-3+TOCE+PEIT sub-group demonstrated greater reduction in AFP levels and longer

survival time than the MGN-3+TOCE sub-group. *Conclusion:* MGN-3 in conjunction with IT may be useful for the treatment of hepatocellular carcinoma and warrants further investigation in multiple clinical trials.

Hepatocellular carcinoma (HCC) is the sixth most common cancer worldwide with an estimated 626,000 new cases per year (1, 2). The prognosis for this cancer is poor, with a median survival time of less than six months. The etiology of HCC may be related to three major epidemiological factors, namely hepatitis B and C infection, aflatoxin exposure and cirrhosis (1, 3). Interventional therapies (ITs) include transarterial oily chemoembolization (TOCE), percutaneous ethanol injection therapy (PEIT), radiofrequency ablation (RFA) and cryoablation (4). However, the survival of patients who undergo these therapies is still limited to only two to three years (5). Although it has been suggested that TOCE is an effective treatment for inoperable HCC, an enhanced survival has not yet been validated in randomized trials. Nonetheless, it remains a widely used palliative treatment for HCC cases that are not amenable to resection or ablative therapies. Similarly, several non-randomized studies have demonstrated a beneficial effect of transarterial chemoembolization (TACE), though this was also not confirmed in randomized trials (6). In addition, the side-effects and complications of TACE treatment are severe (7). PEIT has gained wide acceptance as a treatment for HCCs, but is applicable only to a minority of cases.

The poor prognosis for HCC patients coupled with the low efficacy of the available treatments highlights the necessity to find new treatments, or to modify current modes of IT. The present study examined whether combining IT, namely TOCE, PEIT and RFA, with MGN-3, an arabinoxylan rice

Correspondence to: Mamdooh Ghoneum, Ph.D., Charles Drew University of Medicine and Science, Department of Otolaryngology, 1621 E. 120th Street, Los Angeles, CA 90059, U.S.A. Tel: +1 3235635953, Fax: +1 3104746724, e-mail: mghoneum@ucla.edu

Key Words: HCC, angiogram, recurrence, MGN-3.

bran, may increase the survival rate of HCC patients. MGN-3 has been demonstrated to be a potent biological response modifier (BRM) (8-11) and a chemo-sensitizer that sensitizes cancer cells to both death receptor (CD95)-induced apoptosis (12) and to daunorubicin treatment (13). The results demonstrated that HCC patients given IT+MGN-3 showed a higher percent survival than the patients given IT alone.

Patients and Methods

MGN-3. MGN-3 is a denatured hemicellulose that is obtained by reacting rice bran hemicellulose with multiple carbohydrate hydrolyzing enzymes from Shiitake mushrooms. It is an arabinoxyylan with a xylose in its main chain and an arabinose polymer in its side chain (8). Patients were treated with MGN-3 at a dose of 1g per day aliquoted in packets that were taken orally with meals for 12 months simultaneously with IT (see below). MGN-3 was provided by Daiwa Pharmaceuticals Co. Ltd., Tokyo, Japan and is commonly known as Biobran or Lentin Plus 1000.

Patients. Sixty-eight patients (54 males, 14 females) with HCC, aged 30-68 years, participated in the study. The patients were admitted to the 108 Military Central Hospital in Hanoi, Vietnam and were randomly divided into two groups using a computer-generated randomization list: the IT group and the IT+MGN-3 group. Both patients and investigators were blinded. The IT group (30 patients, age 51±17 years: 24 males, 6 females) was treated with IT alone, while the IT+MGN-3 group (38 patients, age 49±19 years: 30 males, 8 females) was treated with IT+MGN-3 for three years (age values represent mean±standard deviation).

Informed consent was obtained from all participants. The study protocol conformed to the ethical guidelines of the 1975 Declaration of Helsinki as reflected in the a priori approval by the 108 Military Central Hospital General Secretary of VASLD Hanoi, Vietnam and by the Institutional Review Board at Charles Drew University of Medicine and Science, Los Angeles, CA, USA.

Prior to treatment, clinical characteristics, tumor characteristics and IT modalities were determined for the patients in each group. The clinical characteristics of the HCC patients prior to treatment were investigated for hepatitis infection and alpha-fetoprotein (AFP) levels. The number of patients with hepatitis B and/or C infection for the IT group was 26 and for the IT+MGN-3 group was 35. The number of patients with AFP levels in three categories (<20, 20-500, and >500 ng/ml) were 11, 7, and 12, respectively, for the IT group and 12, 10 and 16, respectively, for the IT+MGN-3 group. Further clinical findings for HCC patients prior to treatment were examined. The numbers of patients for each symptom in the two treatment groups (IT and IT+MGN-3, respectively) were as follows: fatigue (19 vs. 23), right upper-quadrant pain (22 vs. 27), fever (5 vs. 5), digestive disorder (3 vs. 5), weight loss (8 vs. 9), jaundice (2 vs. 3), hepatomegaly (11 vs. 15) and no symptoms (4 vs. 4). The tumor characteristics of the HCC patients were documented prior to treatment with respect to the number of tumors, tumor site, size and differentiated levels. Table I summarizes the number of patients in the IT group and the IT+MGN-3 group for each of the aforementioned characteristics. Notably, the majority of patients in each group had only one tumor, which was located in the right lobe with a tumor diameter greater than 3 cm. The differentiation levels of the tumors were

characterized as well, moderate and poor in each of the groups. The number of patients in each category was not significantly different between the two groups ($p>0.05$).

Interventional Therapies (IT). IT modalities for the HCC patients included PEIT, TOCE, and RFA. The number of patients in the two groups (IT and IT+MGN-3, respectively) for each modality was as follows: TOCE (11 vs. 13), TOCE+PEIT (14 vs. 20), PEIT (3 vs. 3), TOCE+RFA (2 vs. 2). The number of patients in each modality was not significantly different between the two groups ($p>0.05$). The treatment protocols were dependent on tumor size, the outcome after first treatment and the time to recurrence. For TOCE, adriamycin (20-60 mg/treatment; mean=40 mg/treatment) was mixed with lipiodol (5-20 ml/treatment; mean=12 ml/treatment) and patients were treated every 1-2 months (2-5 treatments/patient; mean=3 treatments/patient). PEIT treatment consisted of ethanol injections (99.5%; 3-15 ml/treatment; mean=8 ml/treatment) given twice per week (mean=6 treatments/patient). For tumors with radius r under 2.5 cm, the total ethanol volume (V) was calculated according to the following formula: $V=4/3\pi(r+0.5)^3$ (14). For RFA treatment, the radiofrequency energy was emitted at a power setting of 60 W for five minutes, 2-4 cycles per treatment, 1-2 times/week. For tumors smaller than 2 cm in length, the patients were treated once; for tumors with length 2-4 cm, the patients were treated 2-3 times, while for larger tumors, the patients were treated 3-5 times. RF data were not included due to the small sample of patients.

Outcome assessment. Patients response to treatment was determined by assessing overall response to treatment, AFP levels, tumor volume, recurrence, and survival.

Overall response to treatment. Patients were assessed for overall response to treatment. A positive response was defined when the patient did not feel fatigued, had a good appetite, had no pain in the liver area, had no fever and a weight gain of 3-5 kg. In addition, for positive response, physical examination would reveal a decrease in liver size and no signs of jaundice or ascites. Patients who did not experience any significant changes in energy levels, pain, fever, weight, jaundice or ascites were placed in the no-response group. An adverse response was defined as a response to treatment opposite of the aforementioned positive response. In addition, most patients in the adverse response group experienced an increase in tumor size or recurrence, as observed *via* imaging, and developed metastasis.

AFP levels. Patient AFP levels were analyzed at six-month intervals for 36 months using an AFP Elisa Kit.

Tumor volume. Tumor volumes were determined at six-month intervals for 36 months using computerized tomography (CT) scanning, and the final tumor measurements are displayed in Table IV.

Recurrence. The secondary outcome measurement was recurrence. Patients were examined for recurrence at six-month intervals for 36 months. If patients had previously experienced disease remission, the presence of tumors was considered recurrent disease. Data were presented as the percentage of patients with recurrent disease.

Survival. The primary outcome measurement was survival and was examined in 2 to 3-month intervals for 36 months.

Table I. Tumor characteristics of patients before treatment.

Characteristics	IT		IT+MGN-3	
	n=30	%	n=38	%
Number of tumors				
Number of patients with 1 tumor	23	76.7	31	81.6
Number of patients with 2 tumors	7	23.3	7	18.4
Total number of tumors	37	100	45	100
Site of tumor				
Right lobe	28	75.7	32	71.1
Left lobe	5	13.5	7	15.6
Both	4	10.8	6	13.3
Size (diameter)				
<3 cm	4	10.8	5	11.1
3-6 cm	20	54.1	23	51.1
> 6 cm	13	35.1	17	37.8
Differentiation				
Well	9	24.3	11	24.5
Moderate	22	59.5	24	53.3
Poor	6	16.2	10	22.2

Table II. Effect of treatment on AFP levels (whole groups). Data represent the mean AFP level. % Change=100 × [(value after treatment) – (value before treatment)] / (value before treatment).

Treatment	Tumor volume (cm ³)	Patients		AFP level (ng/ml)		% Change
		Number	%	Before treatment	After treatment	
IT	≤200	17	57	292.8	316.5	+8%
	>200	13	43	431.7	456.1	+6%
	10-1320 [†]	30	100	353.0	376.97	+7%
IT+MGN-3	≤200	22	58	509.0	356.8	-30%
	>200	16	42	511.4	260.4	-49%
	12-1200 [†]	38	100	510.0	316.2	-38%

[†]Range of tumor volumes in group.

Statistical analysis. Descriptive statistics were used to characterize the subjects (mean, median and standard deviation for continuous variables, and percentages for categorical variables). The chi-square test for categorical variables was used to test the statistical difference between the groups. Significant differences between the groups for the continuous variables were determined using the non parametric median test, Mann Whitney U-test, and Wilcoxon test for the non normally distributed data and by two-sided t-tests, and paired t-tests for normally distributed data when appropriate. The Kaplan-Meier procedure was used to estimate time to death. The Kaplan-Meier method estimated the conditional probabilities at each time point when death occurred and, by taking the product limit of those probabilities, it estimated the survival rate at each point in time. P-values <0.05 were considered significant. Data were analyzed using SPSS version 15 (SPSS, Inc., Chicago, IL, USA).

Table III. Effect of treatment on AFP levels (sub-groups). Data represent the mean AFP level. % change=100 × [(value after treatment) - (value before treatment)] / (value before treatment).

Treatment	Number of patients	AFP level (ng/ml)		% Change
		Before treatment	After treatment	
TOCE	11	433.5	360.9	-16%
TOCE+MGN-3	13	726.1	506.9	-30%
TOCE+PEIT	14	242.2	382.6	+58%
TOCE+PEIT+MGN-3	20	450.0	218.9	-51%

Table IV. Effect of treatment on tumor volume (whole groups). Data represent mean±standard deviation. % Change=100 × [(value after treatment) – (value before treatment)] / (value before treatment).

Treatment	Tumor volume (cm ³)	Patients		Treatment		% Change
		Number	%	Before	After	
IT	≤200	17	57	92.7±12.3	97.6±35	+5%
	>200	13	43	460.4±76.1	454.9±106.7	-1%
	10-1320 [†]	30	100	252.0±258.7	252.5±324.3	+0.2%
IT+MGN-3	≤200	22	58	125.9±13.6	94.1±22.3	-25%
	>200	16	42	481.7±56.6	288.3±47.9	-40%
	12-1200 [†]	38	100	275.7±234.1	175.8±174.9	-36%

[†]Range of tumor volumes in group.

Results

Response to IT treatment. Figure 1 shows that 89% of patients in the IT+MGN-3 group and 80% of patients in the IT group demonstrated a positive response to treatment. In contrast, 5% of patients in the IT+MGN-3 group experienced adverse side-effects compared to 13% for the IT group ($p<0.05$).

AFP levels. AFP levels in HCC patients were examined before and after treatment according to the total tumor volume, and the patients were clustered into sub-groups with tumor volume ≤200 cm³ or >200 cm³ in the IT group and the IT+MGN-3 group, and the final AFP level measurements are displayed in Table II. Using the non-parametric Mann Whitney U-test, the IT group as a whole showed an increase in APF levels of 7% ($p=0.2$), relative to the before treatment value of APF. Specifically, an increase in APF levels ranging from 6 to 8% was noted in patients with a total tumor volume ≤200 cm³ or >200 cm³. In contrast, the IT+MGN-3 group showed a significant decrease of APF levels with a

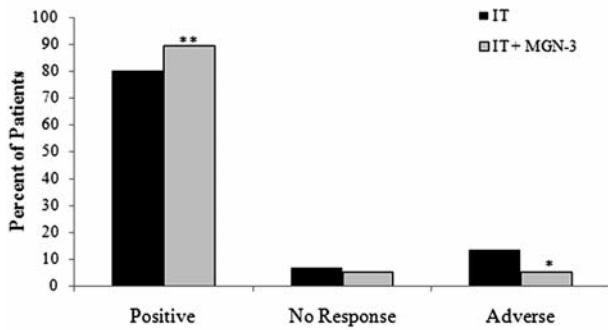


Figure 1. Overall response to treatment. The patients in IT and IT+MGN-3 groups were examined for an overall positive response, no response or adverse response to treatment. Parameters measured included patient fatigue, appetite, liver pain, liver size, fever, weight gain or loss, jaundice and ascites. Response classification is described under Patients and Methods. * $p < 0.05$ and ** $p < 0.01$, as compared to the IT group.

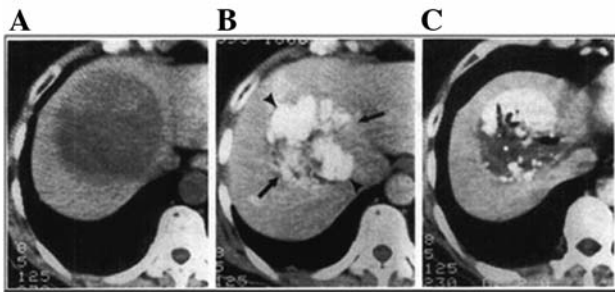


Figure 2. Multi-slice CT scans of an IT+MGN-3 patient. A: Before treatment, the patient had a large tumor in right liver measuring $12 \times 10 \text{ cm}^2$ in plane. B: At three months after treatment, the tumor size decreased to $7 \times 8 \text{ cm}^2$ in plane and had a very high lipiodol marking (arrows). C: At six months after treatment, the tumor size had decreased further to $6 \times 7 \text{ cm}^2$ in plane with lower lipiodol marking, showing liver regeneration.

change of 38% relative to values before treatment ($p < 0.001$). In particular, a significant decrease of APF levels ranging from 30 to 49% ($p < 0.05$) was observed in patients with tumor volumes $\leq 200 \text{ cm}^3$ and $> 200 \text{ cm}^3$ (Table II).

The patients were also sub-grouped according to the IT modality and the changes in AFP levels post-treatment are illustrated in Table III. Patients in the TOCE sub-group demonstrated a 16% decrease in AFP, while patients in the TOCE+MGN-3 sub-group experienced a 30% decrease in AFP. Furthermore, patients in the TOCE+PEIT group had a 58% increase in AFP, while those in the TOCE+PEIT+MGN-3 sub-group demonstrated a 51% decrease in AFP ($p < 0.01$).

Tumor volume. Tumor volumes were examined in HCC patients post-treatment and the results were categorized into two sub-

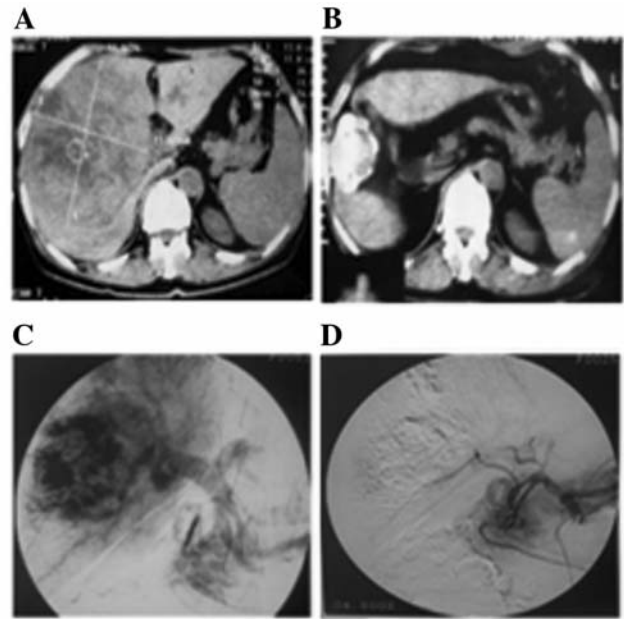


Figure 3. Spinal multi-slice CT scan and angiograms of a IT+MGN-3 patient. A: A multi-slice CT scan before treatment showed that the patient had a large tumor in right liver measuring $14 \times 13 \text{ cm}^2$ in plane. B: After six months of treatment the CT scan showed a decrease in tumor size to $5 \times 6 \text{ cm}^2$ in plane. C: Angiography of the same patient before treatment showed liver artery and portal angiography. D: The angiography taken just after treatment with TOCE showed that the right liver artery had complete embolization.

Table V. Effect of IT modality on tumor volume (sub-groups). % Change = $100 \times [(value \text{ after treatment}) - (value \text{ before treatment})] / (value \text{ before treatment})$.

Treatment	Number of patients	Treatment		% Change
		Before	After	
TOCE	11	272.8	262.5	-4%
TOCE+MGN-3	13	301.5	175.5	-42%
TOCE+PEIT	14	303.4	313.4	+3%
TOCE+PEIT+MGN-3	20	349.5	222.4	-36%

groups according to the whole tumor volume, $\leq 200 \text{ cm}^3$ or $> 200 \text{ cm}^3$. Surprisingly, the IT group had almost no change in tumor volume (0.2%). In contrast, the IT+MGN-3 group had an overall reduction of tumor volume by 36% (Table IV). Specifically, patients in the IT+MGN-3 group with tumor volumes $\leq 200 \text{ cm}^3$ and $> 200 \text{ cm}^3$ experienced a significant decrease in average tumor volume by 25% ($p < 0.05$) and 40% ($p < 0.05$), respectively. However, the patients in the corresponding IT groups showed no significant change in tumor

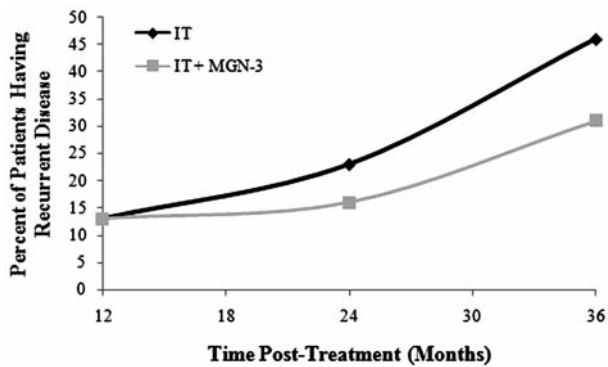


Figure 4. Recurrence of tumors in HCC patients post-treatment for the two groups compared as a whole (IT and IT+MGN-3).

volume. Using the Mann Whitney *U*-test, patients in the IT+MGN-3 group also showed a significant change in tumor volume compared with the control group ($z=2.5$ and $p=0.01$).

The patients were also sub-grouped according to the IT modality and the changes in tumor volume post-treatment are illustrated in Table V. The patients in the TOCE sub-group demonstrated a 4% decrease in tumor volume, while those in the TOCE+MGN-3 sub-group experienced a 42% decrease in tumor volume ($p=0.01$). In addition, patients treated with TOCE+PEIT showed a 3% increase in tumor volume, while those in the TOCE+PEIT+MGN-3 sub-group demonstrated a 36% decrease in the tumor volume ($p<0.01$).

Imaging studies. HCC tumors were analyzed using multi-slice CT and angiography. Imaging results from representative patients of the IT+MGN-3 group are shown in Figures 2 and 3. The multi-slice CT scan in Figure 2 clearly demonstrates that the tumor mass steadily decreased from a size of $12 \times 10 \text{ cm}^2$ to $6 \times 7 \text{ cm}^2$ within a period of six months. The angiogram in Figure 3 shows a decrease in tumor size, from $14 \times 13 \text{ cm}^2$ to $4 \times 5 \text{ cm}^2$ in a period of six months.

Recurrence. Tumor recurrence in the IT and IT+MGN-3 groups was examined every six months for three years. As shown in Figure 4, the recurrence in the IT+MGN-3 group was decreased and maximized at 30 months post-treatment (32%) compared to the IT group (47%) at the same time point. When the patients were sub-grouped according to the IT modality, the statistical analysis demonstrated an insignificant difference in tumor recurrence between the TOCE and TOCE+MGN-3 sub-groups. However, 43% of patients in the TOCE+PEIT sub-group experienced recurrence, compared to 20% in the TOCE+PEIT+MGN-3 sub-group.

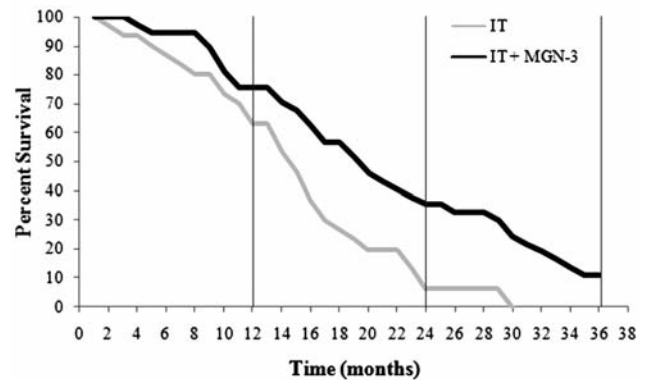


Figure 5. Percent survival in HCC patients post-treatment for the two groups compared as a whole (IT and IT+MGN-3).

Survival. Percentage survival was assessed every 2-3 months in the HCC patients. As shown in Figure 5, patients in the IT group demonstrated a sharp decline in survival. While 63% had survived at the end of the first year, this number dropped significantly to 6.7% by the end of the second year and at 30 months no patients remained alive. In contrast, the IT+MGN-3 group maintained significantly higher survival rates, being 76% at the end of the first year, 35% at the end of the second year, and 11% at the end of the third year. Half of the IT+MGN-3 group survived at 20 months compared with 15 months for the IT group. When the patients were sub-grouped according to the IT modality, the patients in the TOCE sub-group survived for an average of 14.8 months as compared to 16.5 months for the TOCE+MGN-3 sub-group. Notably, patients treated with TOCE+PEIT survived an average of 14.0 months as compared to 23.8 months for the TOCE+PEIT+MGN-3, showing, therefore, an increase in survival time by 10 months.

Discussion

The inability of IT to cause significant necrosis of cancer cells and the low survival rates among HCC patients (3-5%) reflects the inadequacy of ITs in treating this disease (15-17). Therefore, many attempts have been made to improve the efficacy of IT. For example, the use of interferon-alpha (IFN- α) in combination with IT was a focus of many studies, however the results were contradicting. While some studies reported that treatment with 5-FU+IFN- α enhances the survival of patients with advanced HCC (18-20), other studies reported that such treatment is not beneficial for advanced HCC (21, 22). Additionally, other BRMs such as PSK, lentinan, and OK-432, have been shown to have no effect when combined with 5-FU for the treatment of HCC (23).

Realizing the need for further studying on the potential of combination BRM treatments for HCC, the present study

investigated IT in combination with MGN-3. MGN-3 has been previously demonstrated to be a potent BRM (8-11), and may inhibit the production of T regulatory (T reg) cells responsible for cancer-related immunosuppression (24). Furthermore, MGN-3 has demonstrated anticancer activity (11, 25) and improved the survival in cancer patients treated simultaneously with MGN-3 and anticancer drugs (26).

In the current study, the overall results showed that the addition of MGN-3 to IT enhances its anti-neoplastic effect to cause necrosis, and causes a beneficial effect in terms of tumor response rates, recurrence and survival. When the results were analyzed for each IT modality separately, the IT+MGN-3 sub-groups displayed a greater response to treatment, in all aspects compared to the respective IT sub-groups. Notably, the patients in the MGN-3+TOCE+PEIT sub-group demonstrated a greater reduction in AFP levels and longer survival times than those in the MGN-3+TOCE sub-group. However, recurrence, survival, and tumor volume did not significantly differ between the TOCE and TOCE+PEIT sub-groups, suggesting that the combination of the two IT modalities did not increase anticancer efficacy. The exact mechanism underlying the potent anticancer effect of the IT+MGN-3 combinations are not yet fully understood.

Possible mechanisms of MGN-3 action on HCC may be attributed to its immune-modulatory effects. There is much evidence suggesting a major role of the natural killer (NK) cells and dendritic cells in the immune surveillance of neoplastic disease including HCC (27-29). The role of MGN-3 in the potent activation of NK cell activity in cancer patients (30), healthy humans (9, 31) and mice (10) is well documented and was associated with growth suppression of different murine and human malignancies, including HCC (11, 25, 26). MGN-3-induced NK cell activation was mediated through an increase in the NK cell granular content (10) and the expression of key NK cell surface receptors, including CD69, CD25 and ICAM-1 (CD54) (31). Recent studies also showed that MGN-3 is a potent enhancer of human dendritic cell maturation *in vitro* (32) and can suppress T reg lymphocytes in patients with locally limited and metastatic solid tumors including those in the liver (24).

The earlier studies carried out by Suto *et al.* (23) showed no change in survival time or tumor diameter when using the various BRMs with 5-FU. Our contrasting results show changes in survival and tumor growth when treated with MGN-3 +IT. This suggests that the immune modulatory effect by MGN-3 is more potent than previously studied BRMs. In addition, MGN-3 may exert its effect on HCC *via* sensitizing the cancer cells to TOCE and PEIT. Earlier studies showed that MGN-3 has the ability to sensitize human leukemia cells to both death receptor (CD95)-induced apoptosis (12) and human breast cancer cells to the chemotherapeutic agent daunorubicin (13).

Treatment with MGN-3 may reduce the side-effects of TOCE. Earlier studies showed a potential for MGN-3 in reducing chemotoxic effects. These include the protection of animals against gross pathological changes and weight loss produced by chemotherapy (33, 34). Additionally, studies in humans with progressive cancer showed that MGN-3 prolongs life span and improves the quality of life (26). MGN-3 has been shown to be a nontoxic agent and is safe for human consumption (9, 35).

In conclusion, HCC therapy that includes MGN-3 represents a new approach with great clinical potential that could be used in conjunction with other IT modalities to enhance treatment efficacy. The present study provided a rationale for further future clinical studies of this combination of therapies.

References

- Parkin DM, Bray F, Ferlay J and Pisani P: Global cancer statistics 2002. *CA-A Cancer J Clin* 55: 74-108, 2005.
- El Serag HB and Mason AC: Rising incidence of hepatocellular carcinoma in the United States. *N Engl J Med* 340: 745-750, 1999.
- Kew M: Tumors of the Liver. *In: Hepatology: A Textbook of Liver Disease*, 2nd edition Vol 2. Zakim D and Boyer TD (eds.). WB Saunders Company, Philadelphia, PA, USA, pp. 1206-1240, 1990.
- Callstrom MR and Charboneau JW: Technologies for ablation of hepatocellular carcinoma. *Gastroenterology* 134: 1831-1835, 2008.
- Cheng BQ, Jia CQ, Liu CT, Fan W, Wang QL, Zhang ZL and Yi CH: Chemoembolization combined with radiofrequency ablation for patients with hepatocellular carcinoma larger than 3 cm: a randomized controlled trial. *JAMA* 299: 1669-1677, 2008.
- Ramsey DE, Kernagis LY, Soulen MC and Geschwind JFH: Chemoembolization of hepatocellular carcinoma. *J Vasc Interv Radiol* 13: S211-221, 2002.
- Group d'Etude et de Traitement du Carcinome Hepatocellulaire: A comparison of lipiodol chemoembolization and conservative treatment for unresectable hepatocellular carcinoma. *Groupe d'Etude et de Traitement du Carcinome Hepatocellulaire N Engl J Med* 332: 1256-1261, 1995.
- Ghoneum M: Anti-HIV activity *in vitro* of MGN-3, an activated arabinoxylan from rice bran. *Biochem Biophys Res Commun* 243: 25-29, 1998.
- Ghoneum M: Enhancement of human natural killer cell activity by modified arabinoxylan from rice bran (MGN-3). *Int J Immunother* 14: 89-99, 1998.
- Ghoneum M and Abedi S: Enhancement of natural killer cell activity of aged mice by modified arabinoxylan rice bran (MGN-3). *J Pharmacy Pharmacol* 56: 1581-1588, 2004.
- Noaman E, Badr El-Din N, Bibars M, Mossallam AAA and Ghoneum M: Antioxidant potential by arabinoxylan rice bran, MGN-3, represents a mechanism for its oncostatic effect against murine solid Ehrlich carcinoma. *Cancer Lett* 268: 348-359, 2008.
- Ghoneum M and Gollapudi S: Modified arabinoxylan rice bran (MGN-3) sensitizes human T-cell leukemia cells to death receptors (CD95)-induced apoptosis. *Cancer Lett* 201: 41-49, 2003.

- 13 Gollapudi S and Ghoneum M: MGN-3, modified arabinoxylan rice bran, sensitizes human breast cancer cells to chemotherapeutic agent, daunorubicin. *Cancer Detect Prev* 32: 1-6, 2008.
- 14 Ebara M, Ohto M, Sugiura N, Kita K, Yoshikawa M, Okuda K, Kondo F and Kondo Y: Percutaneous ethanol injection for the treatment of small hepatocellular carcinoma: study of 95 patients. *J Gastroenterol Hepatol* 5: 616-626, 1990.
- 15 Vilana R, Bruix J, Bru C, Ayuso C, Sole M and Rodes J: Tumor size determines the efficacy of percutaneous ethanol injection for the treatment of small hepatocellular carcinoma. *Hepatology* 16: 353-357, 1992.
- 16 Bruix J, Castells A, Montanya X, Calvet X, Bry C, Ayuso C, Jover L, Garcia L, Vilana R, Boix L and Rodes J: Phase II study of transarterial embolization in European patients with hepatocellular carcinoma: need for controlled trials. *Hepatology* 20: 643-650, 1994.
- 17 Trevisani F, De Notariis S, Rossi C and Bernardi M: Randomized control trials on chemoembolization for hepatocellular carcinoma: is there room for new studies? *J Clin Gastroenterol* 32: 383-389, 2001.
- 18 Urabe T, Kaneko S, Matsushita E, Unoura M and Kobayashi K: Clinical pilot study of intrahepatic arterial chemotherapy with methotrexate, 5-fluorouracil, cisplatin and subcutaneous interferon alpha-2b for patients with locally advanced hepatocellular carcinoma. *Oncology* 55: 39-47, 1998.
- 19 Sakon M, Nagano H, Dono K, Nakamori S, Umeshita K, Yamada A, Kawata S, Imai Y, Iijima S and Monden M: Combined intraarterial 5-fluorouracil and subcutaneous interferon-alpha therapy for advanced hepatocellular carcinoma with tumor thrombi in the major portal branches. *Cancer* 94: 435-442, 2002.
- 20 Ota H, Nagano H, Sakon M, Eguchi H, Kondo M, Yamamoto T, Nakamura M, Damdinsuren B, Wada H, Marubashi S, Miyamoto A, Dono K, Umeshita K, Nakamori S, Wakasa K and Monden M: Treatment of hepatocellular carcinoma with major portal vein thrombosis by combined therapy with subcutaneous interferon-alpha and intra-arterial 5-fluorouracil; role of type I interferon receptor expression. *Br J Cancer* 93: 557-564, 2005.
- 21 Hamabe ST, Yamasaki T, Saeki I, Harima Y, Okita K, Terai S and Sakaida I: Hepatic arterial infusion chemotherapy for advanced hepatocellular carcinoma: Is the addition of subcutaneous interferon-a-2b beneficial? *Hepatol Res* 39: 223-230, 2009.
- 22 Eun JR, Lee HJ, Moon HJ, Kim TN, Kim JW and Chang JC: Hepatic arterial infusion chemotherapy using high-dose 5-fluorouracil and cisplatin with or without interferon-alpha for the treatment of advanced hepatocellular carcinoma with portal vein tumor thrombosis. *Scand J Gastroenterol* 44: 1477-1486, 2009.
- 23 Suto T, Fukuda S, Moriya N, Watanabe Y, Sasak D, Yoshida Y, and Sakata Y: Clinical study of biological response modifiers as maintenance therapy for hepatocellular carcinoma. *Cancer Chemother Pharmacol* 33: S 145-148, 1994.
- 24 Lissoni P, Messina G, Brivio F, Fumagalli L, Vigoré L, Rovelli F, Maruelli L, Miceli M, Marchiori P, Porro G, Held M, di Fede G and Uchiyamada T: Modulation of the anticancer immunity by natural agents: inhibition of T regulatory lymphocyte generation by arabinoxylan in patients with locally limited or metastatic solid tumors. *Cancer Therapy* 6: 1011-1116, 2008.
- 25 Badr El-Din NK, Noaman E and Ghoneum M: *In vivo* tumor inhibitory effects of nutritional rice bran supplement MGN-3/BioBran on Ehrlich carcinoma-bearing mice. *Nutrition Cancer* 60: 235-244, 2008.
- 26 Takahara K and Sano K: The life prolongation and QOL improvement effect of rice bran arabinoxylan derivative (MGN-3, BioBran) for progressive cancer. *Clin Pharmacol Therapy* 14: 267-271, 2004.
- 27 Brookes RH, Kew MC and Rabson AR: Depressed natural cytotoxicity but normal natural killer cytotoxic factor (NKCF) production by mononuclear cells derived from patients with hepatocellular carcinoma. *Cancer Immunol Immunother* 25: 149-152, 1987.
- 28 Chuang WL, Liu HW and Chang WY: Natural killer cell activity in patients with hepatocellular carcinoma relative to early development and tumor invasion. *Cancer* 65: 926-930, 1990.
- 29 Engleman EG: Dendritic cell-based cancer immunotherapy. *Semin Oncol* 30(3 Suppl 8): 23-29, 2003.
- 30 Ghoneum M and Brown J: NK immunorestitution of cancer patients by MGN-3, a modified arabinoxylan rice bran (study of 32 patients followed for up to 4 years). *In: Anti-aging Medical Therapeutics*, Vol. III. Klatz R and Goldman R (eds.). Health Quest Publications, Marina del Rey, CA, USA, pp. 217-226, 1999.
- 31 Ghoneum M and Jewett A: Production of tumor necrosis factor-alpha and interferon-gamma from human peripheral blood lymphocytes by MGN-3, a modified arabinoxylan from rice bran, and its synergy with interleukin-2 *in vitro*. *Cancer Detect Prev* 24: 314-324, 2000.
- 32 Cholujova D, Jakubikova J and Sedlak J: BioBran-augmented maturation of human monocyte-derived dendritic cells. *Neoplasma* 56: 89-95, 2009.
- 33 Endo Y and Kanbayashi H: Modified rice bran beneficial for weight loss of mice as a major and acute adverse effect of cisplatin. *Pharmacol Toxicol* 92: 300-303, 2003.
- 34 Jacoby HI, Wnorowski G, Sakata K and Maeda H: The effect of MGN-3 on cisplatin and adriamycin induced toxicity in the rat. *J Nutraceut Funct Med Foods* 3: 3-11, 2001.
- 35 Tazawa K: *BioBran/MGN-3: Basic and Clinical Application to Integrative Medicine*. Iyakushuppan Co. Publishers, Japan, 2003.

Received September 14, 2010

Revised October 28, 2010

Accepted October 29, 2010